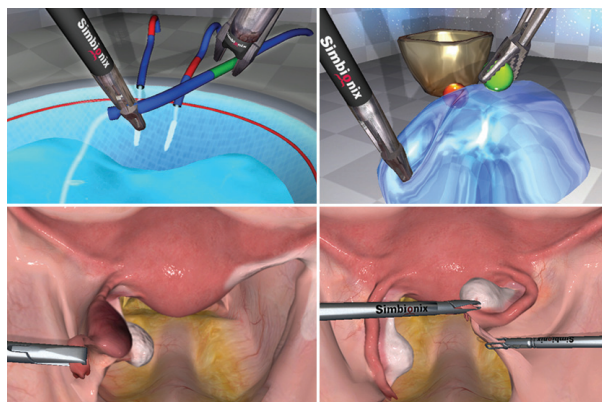


# Basic Laparoscopic Gynecology Skills and Procedures Course



a predetermined level of proficiency as well as defining the mode of training on the simulator.

## 2. Basic Gynecological Procedure Training - Personal Goal Setting

7 patient cases: Laparoscopic tubal sterilization, salpingostomy, salpingectomy and salpingo-oophorectomy. Trainees encounter a range of patient pathologies and gain experience with various techniques and surgical instruments. Included are a variety of complications and emergency situations such as bleeding at the implantation site, a ruptured fallopian tube and a blood-filled abdominal cavity.

## Description

The aim of this course is to allow practicing surgeons as well as residents/fellows and medical students to acquire basic level skills in laparoscopic gynecology including hands-on simulation-based training of essential OB-GYN procedures. The course is designed in two components:

### 1. Proficiency-Based Basic Laparoscopic Skills Training

Training within a proficiency-based virtual reality curriculum may reduce errors during real surgical procedures. The basic skills training within this curriculum is based on Development of a Virtual Reality Training Curriculum for Laparoscopic Cholecystectomy (Darzi et al. British Journal of Surgery 2009; 96: 1086–1093). The aim of the training curriculum is for an individual to acquire skills and reach a predetermined level of proficiency before progressing to more challenging cases.

The study, conducted by the Department of Biosurgery and Surgical Technology at St. Mary's Campus at Imperial College of London, defined, tested and validated a whole-procedure virtual reality training curriculum for Laparoscopic Cholecystectomy on the Simbionix LAP Mentor™ using structured scientific methodology. The curriculum clearly defines

### Continued Training -

#### The Total Laparoscopic Hysterectomy Curriculum

The 'Total Laparoscopic Hysterectomy Training Course for the Simbionix LAP Mentor' is an advanced GYN procedure curriculum for participants desiring advanced training. The course provides repetitive practice of surgical skills required for the procedure, in a safe and reproducible environment, as well as exposure to complications encountered during the laparoscopic hysterectomy procedure including ureteral and bowel injury.

#### This course was written in collaboration with:

Larry R Glazerman MD, MBA, FACOG. Associate Professor and Director, Minimally Invasive Gyn Surgery. Co-Director, USF Center for the Advancement of Minimally-Invasive Pelvic Surgery University of South Florida College of Medicine.

Stuart Hart, MD, FACOG, FACS. Assistant Professor, Division of Female Pelvic Medicine and Reconstructive Surgery. Department of Obstetrics and Gynecology. Co-Director, USF Center for the Advancement of Minimally-Invasive Pelvic Surgery. Medical Director, Tampa Bay Research and Innovation Center (TBRIC). University of South Florida College of Medicine.

## Objectives

- ◆ Practice and acquire competence in basic laparoscopic skills: Camera manipulation 0°; Camera Manipulation 30°; Eye-hand coordination; Clip application; Clipping and grasping; Two-handed maneuvers; Cutting; Electrocautery; Translocation of objects.
- ◆ Practice fundamental GYN procedures: Laparoscopic tubal sterilization, salpingostomy, salpingectomy and salpingo-oophorectomy.
- ◆ Encounter a range of patient pathologies.
- ◆ Gain experience with various techniques and surgical instruments.
- ◆ Learn to avoid and control complications and emergency situations such as bleeding at the implantation site, a ruptured fallopian tube and a blood-filled abdominal cavity.

## Specialties

Gynecology

## Target Audience

Practicing surgeons, as well as residents/fellows and medical students, interested in hands-on simulation-based training of essential GYN procedures.

## Assumptions

It is recommended to include a cognitive skills module at the beginning of the training program. No previous procedural or technical knowledge is required.

## Suggested Time Length

Suitable for 2 day training courses or for distributed training.

## Authors

### **This course was written in collaboration with:**

Larry R Glazerman MD, MBA, FACOG. Associate Professor and Director, Minimally Invasive Gyn Surgery. Co-Director, USF Center for the Advancement of Minimally-Invasive Pelvic Surgery University of South Florida College of Medicine.

Stuart Hart, MD, FACOG, FACS. Assistant Professor, Division of Female Pelvic Medicine and Reconstructive Surgery. Department of Obstetrics and Gynecology. Co-Director, USF Center for the Advancement of Minimally-Invasive Pelvic Surgery. Medical Director, Tampa Bay Research and Innovation Center (TBRIC). University of South Florida College of Medicine.

### **The Essential Gynecology Module was created in collaboration with:**

M. Jonathon Solnik, MD, Director, Minimally Invasive Gynecologic Surgery, Assistant Residency Program Director, Dept OB/Gyn, Cedars-Sinai Medical Center, Assistant Clinical Professor, Dept OB/Gyn, The David Geffen School of Medicine at UCLA.

Prof. Goldenberg Mordechai, Roy Mashlach, MD, Minimally Invasive Gynecologic Surgery, Sheba Medical Center at Tel Hashomer.

J. Eric Jelovsek, M.D. , Assistant Professor of Surgery, Cleveland Clinic Lerner College of Medicine, Case Western Reserve University.

Dr. Amir Szold, Head of Surgical Endoscopy Unit, Sorasky Medical Center Tel-Aviv.



## AccessSurgery References:

A subscription to AccessSurgery is required for full access to this content. Contact your institution to find out if it already has a subscription or to obtain an account. If your institution does not subscribe to AccessSurgery, you can purchase an annual or short-term subscription.

Morton DA, Foreman KB, Albertine KH. Chapter 12. Pelvis and Perineum. In: Morton DA, Foreman KB, Albertine KH, eds. *The Big Picture: Gross Anatomy*. New York: McGraw-Hill; 2011. <http://www.accessmedicine.com/content.aspx?aID=8666740>.

- ◆ Pelvic Innervation <http://www.accessmedicine.com/content.aspx?aID=8666779>.
- ◆ Pelvic Vasculature <http://www.accessmedicine.com/content.aspx?aID=8666766>.
- ◆ Ureters and Urinary Bladder <http://www.accessmedicine.com/content.aspx?aID=8666818>.

Rogers VL, Worley KC. Chapter 19. Obstetrics & Obstetric Disorders. In: McPhee SJ, Papadakis MA, Rabow MW, eds. *CURRENT Medical Diagnosis & Treatment 2012*. New York: McGraw-Hill; 2012. <http://www.accessmedicine.com/content.aspx?aID=9353>.

- ◆ Ectopic Pregnancy <http://www.accessmedicine.com/content.aspx?aID=9508&searchStr=ectopic+pregnancy>.

Schorge JO, Schaffer JI, Pietz J, Halvorson LM, Hoffman BL, Bradshaw KD, Cunningham FG. Chapter 7. Ectopic Pregnancy. In: Schorge JO, Schaffer JI, Pietz J, Halvorson LM, Hoffman BL, Bradshaw KD, Cunningham FG, eds. *Williams Gynecology*. New York: McGraw-Hill; 2008. <http://www.accessmedicine.com/content.aspx?aID=3152827>.

- ◆ Ectopic Pregnancy <http://www.accessmedicine.com/content.aspx?aID=3152827&searchStr=ectopic+pregnancy#3152827>.

Reynolds R, Loar PV. Chapter 39. Gynecology. In: Doherty GM, ed. *CURRENT Diagnosis & Treatment: Surgery*. 13th ed. New York: McGraw-Hill; 2010. <http://www.accessmedicine.com/content.aspx?aID=5313480>.

- ◆ Surgery for Benign Fallopian Tube Disease <http://www.accessmedicine.com/content.aspx?aID=5313894&searchStr=ectopic+pregnancy#5313894>.

Schorge JO, Schaffer JI, Pietz J, Halvorson LM, Hoffman BL, Bradshaw KD, Cunningham FG. Chapter 41. Surgeries for Benign Gynecologic Conditions. In: Schorge JO, Schaffer JI, Pietz J, Halvorson LM, Hoffman BL, Bradshaw KD, Cunningham FG, eds. *Williams Gynecology*. New York: McGraw-Hill; 2008. <http://www.accessmedicine.com/content.aspx?aID=3166442>.

- ◆ 41-29 Laparoscopic Sterilization <http://www.accessmedicine.com/content.aspx?aID=3167454>
- ◆ 41-30 Laparoscopic Salpingectomy <http://www.accessmedicine.com/content.aspx?aID=3167512>
- ◆ 41-25 Salpingectomy and Salpingostomy <http://www.accessmedicine.com/content.aspx?aID=3167247>.
- ◆ 41-27. Oophorectomy <http://www.accessmedicine.com/content.aspx?aID=3167310&searchStr=ovariectomy>.
- ◆ 41-34 Laparoscopic Salpingo-Oophorectomy <http://www.accessmedicine.com/content.aspx?aID=3167635>.

# Task Descriptions and Curriculum Steps

## Part 1 - Basic Skills

### 1.1 Introduction to Training

**Instructions:**


Before each task is performed, provide a full demonstration by an experienced operator, with an opportunity for the participant to ask questions.

Suggested time length for the familiarization period is approximately 30 minutes.

### 1.2 Nine Basic Tasks - Training

**Instructions:**


Nine tasks are performed twice on the same day in two sessions, with a break of more than one hour between each session.



#### Task 1 - Camera Manipulation 0°

**Task Description:**


Using a 0° camera, locate and snap photographs of ten balls, in an abstract environment.



#### Task 2 - Camera Manipulation 30°

**Task Description:**

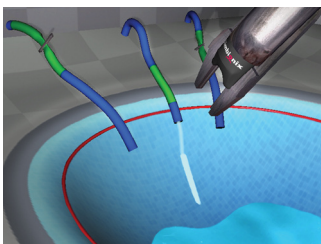
Using a 30° angled camera, locate and snap photographs of ten balls, in an abstract environment.



#### Task 3 - Eye-Hand Coordination

**Task Description:**

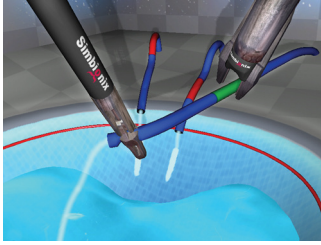
Locate each flashing ball and touch it with the tool of the appropriate color.



#### Task 4 - Clip Application

**Task Description:**


Clip leaking ducts within a specified segment, before the pool fills.



### Task 5 - Clipping and Grasping

**Task Description:**


Safely grasp and clip leaking ducts within a specified segment, before the pool fills.



### Task 6 - Two-Handed Maneuvers

**Task Description:**


Use two graspers to locate the balls within the jelly mass and then place them in the endobag.



### Task 7 - Cutting

**Task Description:**


Safely grasp and clip leaking ducts within a specified segment, before the pool fills.



### Task 8 - Electrosurgery

**Task Description:**

Use a hook to burn the highlighted band, while retracting other bands with an accessory instrument.



### Task 9 - Translocation of Objects

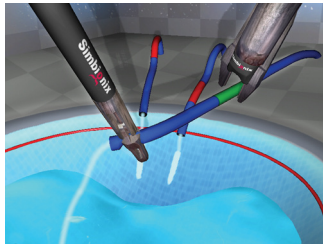
**Task Description:**

Manipulate object with two graspers, and place it into the orientation of the matching transparent object with a minimum number of translocations.

### 1.3 Two Basic Tasks – Demonstration of Proficiency

#### Instructions:

Training is completed when all of the following skill levels are reached in two consecutive sessions.



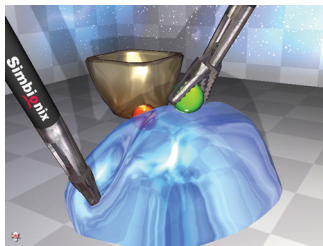
#### Task 5 - Clipping and Grasping

##### Task Description:

Safely grasp and clip leaking ducts within a specified segment, before the pool fills.

##### Required Skill Level

Time taken < 100 s



#### Task 6 - Two-Handed Maneuvers

##### Task Description:

Use two graspers to locate the balls within the jelly mass and then place them in the endobag.

##### Required Skill Level

Total time taken < 90 s

Total number of movements < 100

Total path length < 440 cm

## Part 2 – Gynecology Procedures

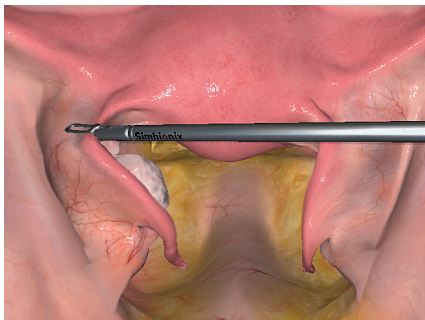
7 patient cases: Laparoscopic tubal sterilization, salpingostomy, salpingectomy and salpingo-oophorectomy. Trainees encounter a range of patient pathologies and gain experience with various techniques and surgical instruments. Included in this module are a variety of complications and emergency situations such as bleeding at the implantation site, a ruptured fallopian tube and a blood-filled abdominal cavity.

Following performing each patient case, the trainee is required to analyze his/her performance report and set personal standards for improvement.

### 2.1 Tubal Ligation

#### Objectives:

- ◆ Demonstrate knowledge of normal pelvic anatomy, specifically the fallopian tube.
- ◆ Handle the normal tissue of the fallopian tube and ovary while avoiding unnecessary trauma and providing optimal exposure.
- ◆ Perform a tubal ligation



#### Essential GYN Module Case 1: Tubal Ligation

##### Medical History:

32 year old Gravida 3, Para 3 comes to your office to discuss contraceptive options. She is happily married, has three healthy children and desires permanent contraception. She used birth control pills in the past that would sometimes exacerbate migraine headaches. Her husband declines vasectomy and she does not feel comfortable using an intrauterine device. A laparoscopic tubal ligation has been scheduled for the patient.

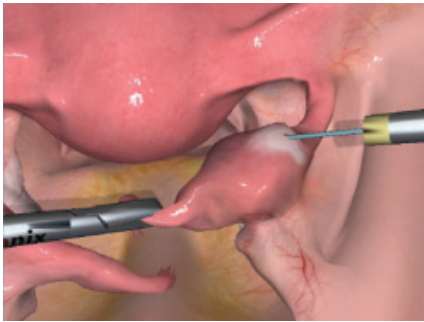
##### Pathology:

None.

## 2.2 Ectopic Pregnancy – 5 Cases

### Objectives:

- ◆ Perform proper inspection of the pelvis.
- ◆ Perform proper evacuation of hemoperitoneum.
- ◆ Determine the appropriateness of salpingostomy versus salpingectomy as the initial surgical strategy
- ◆ In case of salpingostomy:
  - Demonstrate proper technique to control hemostasis from the implantation site, while minimizing thermal spread to the tube.
  - Demonstrate proper use of irrigation at the site with heavy zoom with the camera and light irrigation and suction.
  - Demonstrate the ability to convert to salpingectomy when the case does not seem to be improving with hemostasis attempts.
- ◆ In case of salpingectomy:
  - Perform proper removal of the ectopic pregnancy by performing salpingectomy.
  - Perform proper removal of the ectopic using an endobag removal device.
  - Perform proper inspection after removal of the ectopic for hemostasis of the remaining tube.



### Essential GYN Module Case 2: Isthmic Ectopic Pregnancy

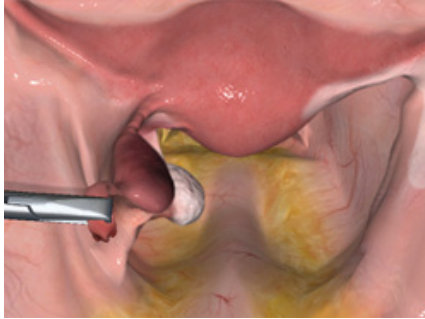
#### Medical History:

A 36 year old female Gravida 1 Para 0 presents to the clinic to have an ultrasound. She is being followed for infertility and is on her first month of ovulation induction. She reports mild cramping. An ultrasound shows a 2 cm adnexal mass in the left tube that is separate from the ovary and nothing in the uterus. Her Beta HCG is 2630. You discuss medical management of her ectopic but she declines use of Methotrexate and desires to “just get this over with.” You schedule her for laparoscopic salpingostomy.

#### Pathology:

A right isthmic ectopic pregnancy.





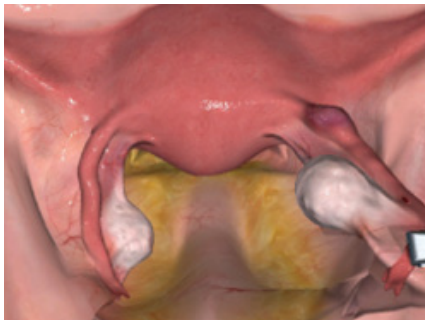### Essential GYN Module Case 3: Isthmic Ectopic Pregnancy

#### Medical History:

A 19 year old Gravida 2 Para 0 presents to the emergency department complaining of increasing pelvic pain, cramping, and bleeding. Her abdomen is tender without rebound or guarding. She has a history of Chlamydia has had one previous ectopic on her right side and underwent a laparoscopic right salpingectomy. Her vital signs are stable. A Beta HCG returns and is 2306 and hematocrit is 37. A pelvic ultrasound shows a left adnexal mass approximately 4 cm in diameter. She has a new partner and definitely wants children in the future if possible.

#### Pathology:

A left isthmic ectopic pregnancy. The right tube has previously been removed.



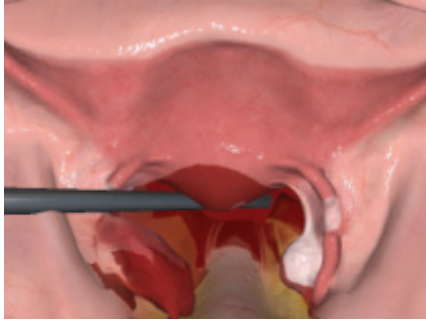
### Essential GYN Module Case 4: Small Ampullary Ectopic Pregnancy

#### Medical History:

A 32-year-old Gravida 3 Para 2 presents to the emergency department complaining of increasing pelvic pain, cramping and bleeding. A pelvic ultrasound shows a left adnexal mass approximately 1 cm in diameter that is separate from the normal appearing ovary. The patient lacks risk factors for an ectopic pregnancy such as a history of PID, operative trauma, or tumors. Because she wishes to retain her fertility, you schedule her for laparoscopic salpingostomy.

#### Pathology:

A small ectopic pregnancy in the right ampullary tube. Active bleeding starts from the bed of the implantation site. Hemostasis will not be possible and attempts to achieve hemostasis may result in irreversible tubal damage.



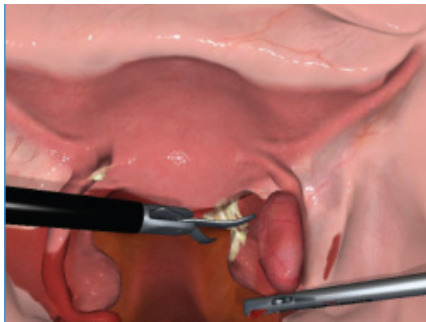## Essential GYN Module Case 5: Ruptured Ectopic Pregnancy Following Sterilization Failure

### Medical History:

You are called to the emergency room to evaluate a 36 year old female Gravida 4, Para 2 who came in for evaluation of severe pelvic pain, cramping, and vaginal spotting. The patient had a bilateral tubal ligation about 4 years prior. She appears stable but uncomfortable lying in the bed on her side. Her blood pressure is 110/75 and pulse is 80. Her abdomen is tender with mild guarding. Pelvic exam shows a closed cervical os with minimal dark blood in the vaginal vault and tenderness on moving the cervix. A beta human chorionic gonadotropin (HCG) level is 2810, hematocrit is 32, and blood type is O positive. An ultrasound shows a 4-5 cm adnexal mass separate from the ovary and nothing in the uterine cavity. There is a moderate amount of fluid in the pelvis. She tells you she does not want any more children in the future. A laparoscopic salpingectomy is scheduled for the patient.

### Pathology:

A ruptured ectopic pregnancy following sterilization failure. The ectopic pregnancy is located in the distal portion of the left fallopian tube.



## Essential GYN Module Case 6: Ectopic Pregnancy

### Medical History:

A 24 year old female Gravida 1 Para 0, presents to the emergency department with abdominal pain not being controlled by pain medications, no vaginal bleeding, and severe menstrual cramping. She is not sure when her last menses was, has a history of Chlamydia and multiple visits to the emergency department for pelvic pain that is usually diagnosed as pelvic inflammatory disease. During physical exam her blood pressure is 100/65, pulse is 92. Her abdomen is tender and she has mild guarding. Her serum HCG is 4250 and hematocrit are 33. A pelvic ultrasound shows nothing in the uterine cavity and a right adnexal mass approximately 5 cm in diameter that is adjacent to but separate from the ovary and a large amount of debris in the pelvis consistent with blood. She is placed on the OR list for laparoscopic salpingectomy.

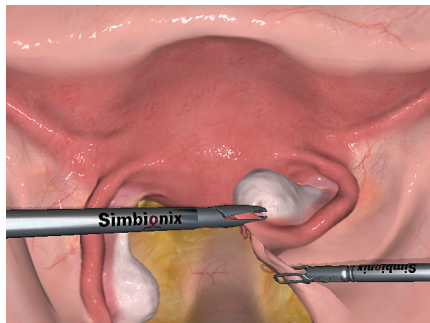
### Pathology:

A ruptured ampullary ectopic pregnancy in the right tube. The left fallopian tube is in bad condition with a clubbed fimbriated end. Adhesions are present in the anatomy.

## 2.3 Prophylactic Salpingo-Oophrectomy

### Prophylactic Oophorectomy - Objectives:

- ◆ To perform proper inspection of the pelvis and abdomen.
- ◆ To identify and avoid the ureter prior to transecting the IP ligament.
- ◆ To perform proper electro-surgery and ligation of the ovarian vasculature and observe for bleeding.
- ◆ To use electro-surgery properly to transect the tube, utero-ovarian ligament and vasculature to remove both the tube and the ovary.
- ◆ To perform the same procedure on the opposite side and collect specimens.



### Essential GYN Module Case 7: Prophylactic Salpingo-Oophrectomy

#### Medical History:

A 39 year old female Gravid 2 Para 2 comes to your office for counseling regarding her risk of ovarian cancer. She is BRCA 1 positive by genetic testing (tested, since multiple family members have been diagnosed with both ovarian and breast cancer at an early age). She has finished childbearing and wishes to reduce her risk of ovarian and breast cancer by getting her ovaries removed. She reports no abnormal symptoms, is healthy, and has never had any abdominal surgery. She is scheduled for laparoscopic prophylactic bilateral salpingo-oophorectomy.

#### Pathology:

None.